

## REVIEW

# Components of the standard oesophageal manometry

J. A. MURRAY,\* R. E. CLOUSE† & J. L. CONKLIN‡

\*Division of Gastroenterology and Hepatology, Mayo Clinic, Rochester, MN, USA

†Division of Gastroenterology, Washington University School of Medicine, St. Louis, MO, USA

‡The Cedars Sinai Medical Center, Los Angeles, CA, USA

**Keywords** motility, oesophagus, standards, testing.

## INTRODUCTION

This document originates from several working groups attempting to standardize the performance and interpretation of oesophageal manometry. The authors present an interpretation of the consensus that articulates the established clinical roles for oesophageal manometry and describes the technical components of a basic, standard oesophageal motility examination.

Members of the working groups all thought that standardizing oesophageal motility testing is a priority for a number of reasons. Perhaps most important, there is a dearth of standardized training for individual practitioners who perform and interpret oesophageal manometry. Training in these techniques is inadequate in most gastrointestinal (GI) training programmes, and practising clinicians often learn from providers of manometry equipment during brief training sessions. In addition, multiple methods are used for performing and reporting oesophageal manometries, making it difficult or impossible to share data between investigators or clinicians.

With the advent of laparoscopic Nissen fundoplication, there has been an explosion of interest in the use of oesophageal manometry as a preoperative diagnostic tool. At the same time, changes in medical practise have placed the conduct of oesophageal manometry into the hands of nurses, medical technicians and

others with no prior experience in the techniques or theory of oesophageal manometry. Indeed, their supervising clinicians often have a minimal understanding of oesophageal motor physiology and the technical underpinnings of oesophageal manometry. We have not attempted to address the specific needs for training of the individual performing the tests. It is apparent that these individuals come from a variety of technical or nursing disciplines and are often regulated quite differently by institutional, regional or national licensing authorities. The people undertaking these studies should have a good working knowledge of the principles of oesophageal anatomy and physiology and a thorough understanding of their equipment as a minimum.

Participants in our working groups felt that providing a specific and detailed description of the components of a standard oesophageal manometry may help clinical practitioners to perform a standardized and reproducible oesophageal manometry that can be interpreted by others. These guidelines are not meant to supplant the practise of those who have developed their own systems over many years and who are considered experts in the field of oesophageal manometry, nor are they meant to be a detailed, advanced handbook of oesophageal manometry. Those detailed methods can be found in several of the publications or books on the topic.<sup>1–3</sup>

This report comes in three parts: a basic description of the functional information derived from a manometry study, a description of the performance of oesophageal manometry, and a description of the important components of the manometry report. The opinions contained reflect the consensus of the working party derived from the American Motility Society (AMS) and European Society of Neurogastroenterology and Motility Society (ESNM). The conclusions are based on published data and on the combined experience of the participants. Input was also received from several

---

### Address for correspondence

Dr. Joseph A. Murray, Professor of Medicine, Division of Gastroenterology and Hepatology, The Mayo Clinic, 200 First Street SW, Rochester, MN, 55905, USA.

Received: 19 February 2003

Accepted for publication: 13 June 2003

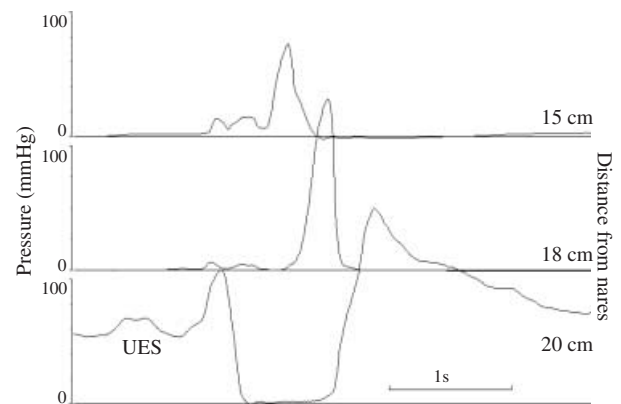
major manufacturers of manometric equipment, but commercial concerns did not enter into the development of this report.

## FUNCTIONAL INFORMATION OBTAINED BY OESOPHAGEAL MANOMETRY

The primary functions of the oesophagus are to transport swallowed materials from the pharynx to the stomach and to prevent the reflux of injurious gastric contents into the oesophagus and airways.<sup>4</sup> The motor activities that allow the oesophagus to accomplish these tasks are governed by complex neuromuscular interactions in three physiologically distinct neuromuscular units: the upper oesophageal sphincter (UES), the body of the oesophagus and the lower oesophageal sphincter (LES).<sup>5</sup> Manometric techniques measure the amplitudes and timing of the pressure changes that, in general, reflect the force and timing of the circular muscle contraction or relaxation.<sup>6,7</sup>

### Upper oesophageal sphincter

The UES is defined physiologically as a 2–4 cm zone of elevated pressure located at the junction of the pharynx and oesophagus. Its muscular components are the cricopharyngeus and a portion of the inferior pharyngeal constrictor, both striated muscles.<sup>8</sup> The ends of the cricopharyngeus insert onto the lateral aspects of the cricoid cartilage. Therefore, the anterior wall of the sphincter is a stiff cartilage, which is resistant to deformation, and the posterior and lateral walls are striated muscle. This imparts a crescent shaped, slit-like appearance to the UES when the cricopharyngeus is in its tonically contracted, resting state.<sup>8</sup> Upper oesophageal sphincter pressures recorded by manometry have two origins: contraction of the sphincter muscle and passive viscoelastic forces produced by the tissues in and around the sphincter, which tend to hold it closed.<sup>8,9</sup> The slit-like configuration of the UES gives rise to an asymmetric pressure profile in the resting sphincter, with pressures being much greater anterior and posterior than laterally.<sup>9,10</sup> Directional pressure sensors-like the perfused side-hole catheter will, therefore, measure different pressures depending upon their orientation within the sphincter.<sup>1,11</sup> Resting UES pressure varies with the state of arousal, and with respiration.<sup>12</sup> In addition, UES pressure is increased reflexively by the presence and movement of the manometry catheter in the sphincter.<sup>13,14</sup> These biomechanical and physiological properties of the UES make it difficult to reliably evaluate pressure in the resting UES. Indeed, published normal values vary quite widely.<sup>15</sup>



**Figure 1** Motor function of the pharynx and upper oesophageal sphincter. This is an example of pharyngeal peristalsis and upper oesophageal sphincter (UES) relaxation produced by a wet swallow. Pressure is on the Y-axis and time is on the X-axis. The numbers to the right indicate distance from the nares. The most distal sensor – bottom trace – is in the UES. The UES is defined as a region of elevated pressure in the proximal oesophagus that decreases with swallowing. A peristaltic sequence is recorded in the pharyngeal sensors above the UES. Note that the timing of the UES relaxation begins before the pharyngeal contraction occurs.

The UES opens during deglutition to allow passage of the swallowed bolus into the oesophagus. The mechanisms contributing to its opening include traction on the anterior wall of the sphincter by contraction of the infrahyoid and suprahyoid muscles during elevation of the larynx, relaxation of the cricopharyngeus and pressure in the swallowed bolus.<sup>8,16</sup> Relaxation of the UES begins as the larynx is elevating, and precedes its opening by about one-tenth of a second.<sup>17</sup> The time that the sphincter remains open and its luminal diameter vary as a function of the bolus size.<sup>18</sup> Closure of the sphincter coincides with arrival of a powerful pharyngeal peristaltic contraction (Fig. 1). This complex neuromuscular sequence is seen manometrically as a rapid drop in resting UES pressure lasting approximately 0.5 s followed by a rise in pressure that may exceed twice the resting UES pressure.<sup>1</sup> This pressure wave may last for a second or so before returning to resting levels (Fig. 1).

### Oesophageal body

The oesophageal body is a 20–22 cm muscular tube that originates at the caudal extent of the cricopharyngeus and extends to the proximal margin of the LES. It is composed of inner circular and outer longitudinal muscle layers that are named according to the axial orientation their constituent muscle cells. The top 5% of the oesophagus – roughly to the level of

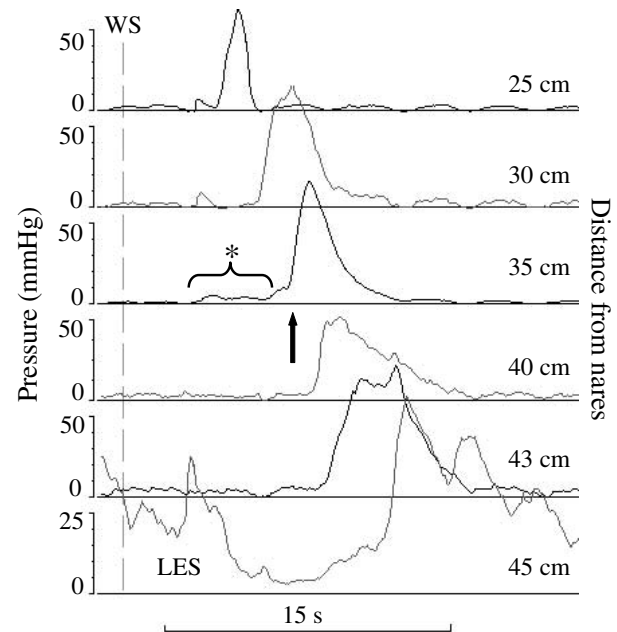
the aortic arch is striated muscle, the middle 35–40% is an admixture of striated and smooth muscle with smooth muscle progressively replacing striated muscle where the bottom 50–60% is entirely smooth muscle.<sup>19</sup> A neural network called the myenteric plexus is sandwiched between the muscular layers.<sup>20</sup>

The innervation of the striated muscle part of the oesophagus is somatic: neurones arising in the nucleus ambiguus travel within the vagus to synapse directly on striated muscle fibres as motor endplates.<sup>21</sup> Peristalsis in the striated muscle oesophagus results from a patterned, sequential activation of these neurones to produce successive contraction of striated circular oesophageal muscles.<sup>21</sup> The extrinsic innervation of the smooth muscle oesophagus is derived from the dorsal motor nucleus of the vagus.<sup>22</sup> These parasympathetic preganglionic fibres travel within the vagus to synapse on neurones within the myenteric plexus.<sup>23</sup> Myenteric neurones supply the terminal motor innervation of the smooth muscle oesophagus. The programming of peristalsis in the smooth muscle oesophagus depends upon a precise interplay among the central nervous system, myenteric plexus and smooth muscle of the oesophagus. The central nervous system behaves as a switch that initiates a peripheral programme in the myenteric plexus and smooth muscle to produce peristalsis.<sup>21</sup> The neuromuscular mechanisms controlling oesophageal motor function are reviewed elsewhere.<sup>24,25</sup>

At rest, the musculature of the normal oesophageal body generates no rhythmic contractions and little tone. Therefore, most intraluminal pressure changes recorded in the quiescent oesophagus are passive, arising from intrathoracic pressure changes associated with respiration (Fig. 6) or with transmitted pressure waves from nearby cardiovascular structures-like the heart or aorta (Fig. 7).

Despite marked regional differences in its neuromuscular makeup and control mechanisms, the oesophagus behaves, at least superficially, in a seamless fashion as a single functional unit. Oesophageal peristalsis is a wave of circular muscle contraction that proceeds into the proximal oesophagus as a continuation of the forceful contraction that follows relaxation of the UES. This ring-like contraction of the circular muscles propagates down the oesophagus to the level of the LES. It propels the swallowed bolus along the oesophagus to the stomach.<sup>26</sup>

Oesophageal peristalsis is recorded manometrically as a pressure wave that moves along the length of the oesophagus (Fig. 2). The peristaltic pressure wave is sometimes preceded by a transitory fall in intraoesophageal pressure that lasts up to 0.5 s. It is



**Figure 2** Normal oesophageal motor function. This is an example of normal oesophageal peristalsis and lower oesophageal sphincter (LES) relaxation. Pressure is on the Y-axis and time is on the X-axis. The numbers to the right indicate distance from the nares. WS indicates the occurrence of a wet (water) swallow. The most distal sensor – bottom trace – is in the LES. The LES is defined as a region of elevated pressure near the gastroesophageal junction that decreases with swallowing. A peristaltic sequence is recorded in the sensors above the LES. The asterisk and bracket identify the pressure in the bolus that precedes the peristaltic contraction (bolus pressure). The beginning of the rapid upstroke of the pressure wave (vertical arrow) corresponds to closure of the oesophageal lumen by the peristaltic contraction.

inconstantly observed and its genesis is unclear. A small increase in intraluminal pressure may also precede the peristaltic pressure wave (Fig. 2). It occurs nearly simultaneously along the length of the oesophagus approximately 1.0 s after the initiation of swallowing and is variable in its amplitude. It is thought to represent pressure within the swallowed bolus as it is propelled ahead of the peristaltic contraction.

The pressure waves produced by the peristaltic contractions traverse the length of the oesophageal body in 5–6 s. They progress at about 3 cm s<sup>-1</sup> in the upper oesophageal body, 5 cm s<sup>-1</sup> along the middle of the oesophageal body, and 2.5 cm s<sup>-1</sup> just above the LES.<sup>27</sup> Their durations are in the range of 2–4 s, and they tend to be of longer duration in the distal oesophagus.<sup>28</sup> The amplitudes of peristaltic pressure waves also vary along the oesophagus, with the amplitude being greater in the proximal and distal oesophagus than in the mid-oesophagus.<sup>28</sup> The

diminution in peristaltic pressure appears to occur over the zone of transition from striated to smooth muscle. The amplitudes of peristaltic pressure waves can normally vary from swallow to swallow. The point at which the peristaltic pressure wave begins its rapid rise (Fig. 2) corresponds with closure of the oesophageal lumen by the peristaltic contraction.<sup>29</sup>

Swallow-induced peristalsis is accompanied by longitudinal muscle contraction that shortens the oesophagus by 2–2.5 cm.<sup>30,31</sup> Longitudinal muscle contraction-like peristalsis, begins in the proximal oesophagus and progresses in a craniocaudal sequence, but it precedes the peristaltic circular muscle contraction.<sup>28</sup> The process of oesophageal shortening is not distinguishable as an intraluminal pressure change.

### Lower oesophageal sphincter

Liebermann-Meffert *et al.* defined the human LES anatomically as thickened band of circular muscle at the gastroesophageal junction.<sup>32</sup> The LES is comprised of two muscular elements. One muscular element, the 'clasp' fibres, is a semicircle of transverse smooth muscle fibres that terminate along the anterior and posterior walls of the oesophagus, and encompass that half of the oesophago-gastric junction next to the lesser gastric curvature. The oesophago-gastric junction adjacent to the greater gastric curvature is left unenclosed by the clasp fibres. The other muscular element the gastric 'sling' fibres is a long band of obliquely oriented smooth muscle that arises from the anterior and posterior gastric body on the lesser gastric curvature.<sup>32</sup> The sling fibres arch around the oesophago-gastric junction adjacent to the gastric greater curvature. The sling fibres do not enclose the side of the oesophago-gastric junction occupied by clasp fibres.

The muscular components of the LES are tonically contracted at rest.<sup>33,34</sup> This closes the lumen at the oesophago-gastric and partitions the oesophagus from the stomach. Physiological mechanisms intrinsic to the LES muscles are responsible for its tonic contraction, but resting tone can be modulated by the activity of both inhibitory and excitatory myenteric neurones.<sup>35,36</sup> In response to swallowing, the LES relaxes to allow passage of the swallowed bolus into the stomach. Swallowing activates vagal efferent fibres that arise in the dorsal motor nucleus of the vagus and terminate on myenteric neurones that constitute a terminal motor innervation to the LES.<sup>37,38</sup> Nitric oxide generated by inhibitory myenteric neurones initiates cellular processes that cause relaxation of LES muscle.<sup>39,40</sup> Detailed descriptions of the mechanisms controlling LES function can be found elsewhere.<sup>24</sup>

The LES is seen as a 2–4 cm wide zone of elevated pressure at the oesophago-gastric junction during oesophageal manometry. The pressure profile of the sphincter is neither radially nor axially symmetric. This occurs primarily because the muscular elements that make up the sphincter, the clasp fibres and gastric sling fibres, do not form a symmetric structure.<sup>32</sup> In addition, the forces generated by their contraction are not in the same direction. Variability of the pressure profile also results from irregularity of mucosal folds, and impingement upon the oesophagus by adjacent structures-like the diaphragm.<sup>41</sup> The recorded LES pressure will, therefore, depend upon the orientation of the pressure sensor within the sphincteric segment. A component of the pressure recorded at the LES is contributed by diaphragmatic contraction.<sup>41,42</sup> Contraction and relaxation of the diaphragm during respiration is commonly seen as cyclical variations in resting LES pressure (Fig. 6).<sup>43</sup> Lower oesophageal sphincter pressure is influenced by drugs, foods, gastric distention, intra-abdominal pressure, hormones, and the phase of the migrating myoelectrical complex.<sup>44</sup> The minute-to-minute variation in resting LES pressure may range from 4 to 9 mmHg, and during prolonged recordings the pressure varies from  $10 \pm 5$  to  $55 \pm 10$  mmHg in normal individuals.<sup>19,45–48</sup> The measured pressure also depends directly on the outer diameter of the manometry catheter.<sup>49–51</sup> These are all reasons why establishing 'normal' values for LES pressure are fraught with difficulty.

Swallowing initiates a relaxation of the tonically contracted LES that is registered during oesophageal manometry as a drop in LES pressure (Fig. 2). This drop in pressure begins approximately 2–3 s after the swallow is initiated, well after the peristaltic contraction passes into the proximal oesophageal body. It lasts in the range of 5–10 s, and is followed by a transient pressure increase that may reach twice the resting LES pressure. This transitory pressure peak coincides with arrival of the peristaltic contraction.

### MANOMETRY EQUIPMENT

The tools of the manometry trade have been refined over many years to the point where they are standardized, reasonably quantitative and reliable within limits. All GI manometry setups consist of two hardware components: a pressure sensor/transducer, which is able to sense changes in intraluminal pressure and convert what is detected into an electrical signal, and a recording device that amplifies the signal and stores it. Two types of sensing/transducer devices are currently used for oesophageal manometry, water-perfused cath-

eters coupled to volume-displacement transducers or solid-state strain gauge transducers.

The water-perfused catheter is a bundle of thin polyvinyl tubes. Each tube has an outward facing opening (side-hole) near its distal end. Each opening is at a different level, usually equidistant from its neighbour, so that pressure can be measured simultaneously at several locations along the catheter length. A low-compliance pneumo-hydraulic pump is used to slowly perfuse the tubes with bubble-free water.<sup>52</sup> The pressure in each tube is sensed and converted to an electrical signal by a volume-displacement transducer. The recorded pressure rises when the flow of water through the side-hole of a tube is impeded by circumferential contraction of the wall of the oesophagus.

Water-perfused oesophageal manometry catheters typically are configured with three to eight pressure sensing side-holes. Catheters with greater numbers of sensors are used for high-resolution manometry. The side-holes usually are spaced at 5 cm intervals on catheters with three sensors, while most eight channel catheters have side-holes spaced at 3 cm intervals. Using of the eight channel catheter assembly confers two advantages: the catheter does not have to be repositioned during the study to evaluate the motor function of the entire oesophagus, and its more closely spaced sensors are less likely to miss localized motor events. It can be very difficult to reliably record the motor function of the oesophageal sphincters with manometry catheters using point sensors-like the water-perfused side-hole. Ideally, a pressure sensor located in a sphincteric segment would stay within sphincteric lumen during swallowing. This is often not the case because both the UES and LES move cephalad with swallowing; the UES because the larynx elevates, and the LES, because the oesophagus shortens. As a result of this movement, the pressure sensor may drop out of the high-pressure zone. Such positional changes are recorded as decreases in pressure that might be mistakenly interpreted as a relaxation. To circumvent this problem a sleeve sensor commonly called the Dent sleeve was developed.<sup>53</sup> The sleeve sensor consists of a 6 cm long silicone rubber membrane covering a flattened segment of the distal catheter assembly. A side-hole is located beneath the membrane, so water exiting the catheter flows beneath the membrane. Deformation of the membrane anywhere along its length changes resistance to flow along the sleeve assembly. The change in flow is registered as a pressure change. In practise, the sensor measures the highest pressure anywhere along its 6-cm length. Despite its advantages over the side-hole sensors in detecting incomplete LES relaxation, there can be problems associated with the

use of the Dent sleeve. It is unusable in the UES and pharynx because its frequency-response characteristics do not allow it to faithfully record the rapid pressure transients produced by striated muscles. The sleeve sensor also misrepresents the duration of LES relaxation because it senses arrival of the peristaltic pressure wave just above the LES, at a time when the LES is still relaxed. The result is an artefact seen as LES relaxation that is short in duration.

While the recorded amplitudes and timing of the pressure changes reflect the force and timing of the circular muscle contraction, the fidelity of the pressure recording depends upon physical characteristics of the recording system-like its compliance, the rate of perfusion, and the diameter of the catheter side-hole.<sup>52</sup> To faithfully measure pressure transients produced by circular muscle contraction in the entire body of the oesophagus, the manometry system must be able to detect pressure transients that have a rate of rise ( $dP/dt$ ) in the range of  $400 \text{ mmHg s}^{-1}$  (51). Commercially available water-perfused catheter/volume-displacement transducer/pneumo-hydraulic pump combinations meet this specification. The same cannot be said for the use of perfused catheters in recording pharyngeal motor activity. Swallow-induced pressure transients in the distal pharynx have a  $dP/dt$  on the order of  $4000 \text{ mmHg s}^{-1}$ , far above the frequency-response characteristics of perfused manometry systems.<sup>54,55</sup>

Pressure artefacts may be encountered in a number of situations. Occlusion of the catheter by debris or compression causes a false rise in pressure. Introducing air bubbles into the catheter or losing pressurization in the pneumo-hydraulic pump dampens the responsiveness of the recording system. People performing manometry with water-perfused catheter systems must understand these possible sources of error.<sup>56</sup>

The other commonly used sensing device is a linear array of miniature, solid-state strain gauge transducers spaced at regular intervals along a flexible tube.<sup>28</sup> Outputs from the strain gauges are passed to an amplifier and then to a recording device, most commonly a computer. Solid-state manometry systems have some advantages over water-perfused catheters. Solid-state catheters have much higher frequency-response characteristics, making them able to faithfully record the much faster pressure transients produced by the striated muscles of the pharynx and UES. Solid-state devices also require less technical expertise and are less cumbersome to use. These devices have the disadvantages of being more expensive and more susceptible to damage; repairs can be expensive and may keep the catheter out of service for long periods. Solid-state pressure transducers-like the

perfused side-hole, have point sensors that may migrate from a sphincteric segment with swallowing. Solid-state devices that record over longer segments have been designed, but are not commonly utilized. No formal studies addressing the difference in cost of use of each system have been undertaken although acquisition cost for perfused catheters is less than solid-state catheters.

## INDICATIONS FOR OESOPHAGEAL MANOMETRY

The indications for oesophageal manometry were critically reviewed previously<sup>15</sup> and are summarized in Table 1. A normal oesophageal manometry is depicted in Fig. 2.

The primary indication for oesophageal manometry is the evaluation of oesophageal dysphagia not definitively diagnosed by means of endoscopy and/or radiographic studies.<sup>15</sup> Significant oesophageal pathology such as oesophagitis, oesophageal ulcers or strictures, and oesophageal cancer should be identified prior to performing manometry. Oesophageal manometry also finds utility in the evaluation of non-cardiac chest pain after cardiac disease, musculoskeletal pain, anxiety disorders and those oesophageal diseases outlined above have been excluded. Unfortunately, those oesophageal motor abnormalities that are unambiguously associated with dysphagia and/or non-cardiac chest pain are relatively uncommon disorders-like achalasia (Fig. 3) and diffuse oesophageal spasm (Fig. 4). Non-specific spastic motor disturbances including the nutcracker oesophagus (Fig. 5) may also be associated with chest pain and dysphagia, but their pathogenesis and relationship to symptoms are less clear. Oesophageal manometry is the standard method by which achalasia is diagnosed.<sup>15</sup> It may also be of use in evaluating generalized GI motility disorders.

Oesophageal manometry was used in the past to determine oesophageal involvement by connective tissue diseases, primarily because oesophageal

dysmotility was one of the diagnostic criteria for CREST syndrome. However, the CREST syndrome is no longer recognized as a distinct diagnostic entity. Manometry can be used to determine oesophageal involvement in systemic sclerosis (SSc), as up to 90% of patients with this connective tissue disease have oesophageal motor dysfunction (Fig. 6). Typical manometric findings of SSc include low amplitude or absent peristaltic pressure waves in the smooth muscle oesophagus and a low-pressure LES. In general, the striated muscle portion of the oesophagus functions normally. These motor abnormalities are, however, not specific for SSc, and can be seen in other connective tissue diseases.

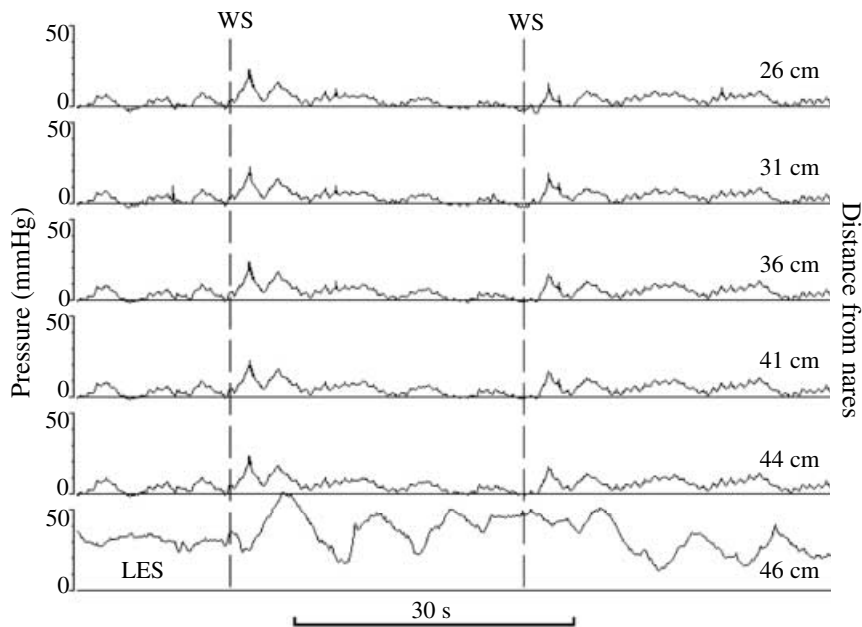
Oesophageal manometry is widely accepted as the most accurate method for identifying the upper boarder of the LES prior to placement of a 24-h ambulatory pH catheter.<sup>56,57</sup> It may be of limited utility in the evaluation of oesophageal motor function prior to performing a fundoplication for gastroesophageal reflux disease, while there are several schools of thought on this point.<sup>15,58</sup> Some surgeons are hesitant to perform a fundoplication if a patient has significant oesophageal hypomotility (e.g. amplitudes of peristaltic pressure waves in the distal oesophagus of less than 30 mmHg or 30% or more non-transmitted contractions) or abnormal oesophageal motor function. Others modify their surgical approach based upon the results of manometry, employing a loose wrap when there is a motor disturbance. The correct thresholds for tailoring surgical technique remain unclear, however, preoperative manometry is not a strong predictor of postoperative dysphagia.<sup>59</sup> In selected cases, oesophageal manometry may be of help in the evaluation of postoperative dysphagia after a fundoplication or treatment of achalasia with Heller myotomy, balloon dilation or botulinum toxin injection.

## Performance of manometry

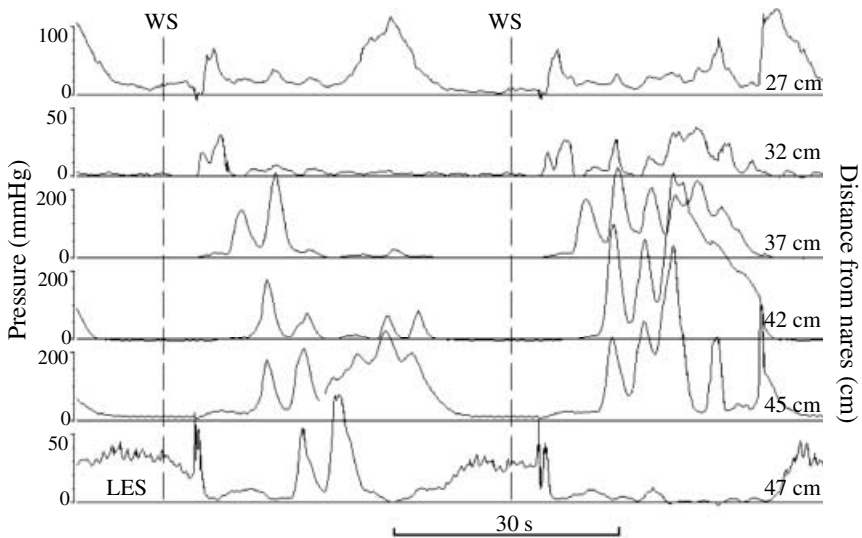
*Patient preparation.* Ideally, the patient should be kept fasting for at least 6 h prior to the procedure: 12 h if achalasia is suspected. This practise helps to protect the patient from aspirating intragastric or intraoesophageal contents. Medications that may alter oesophageal motility should be avoided unless required for the patient's well-being. Such agents include caffeine, calcium-channel blockers, organic nitrates, prokinetic agents, loperimide,  $\beta$ -adrenergic antagonists, opiate antagonists or agonists and anticholinergic agents including tricyclic antidepressants. Appropriate explanation should be given to the patient and consent obtained and documented. If sedation must be used, this should be recorded in the manometric report. Local

**Table 1** Clinical roles for oesophageal manometry

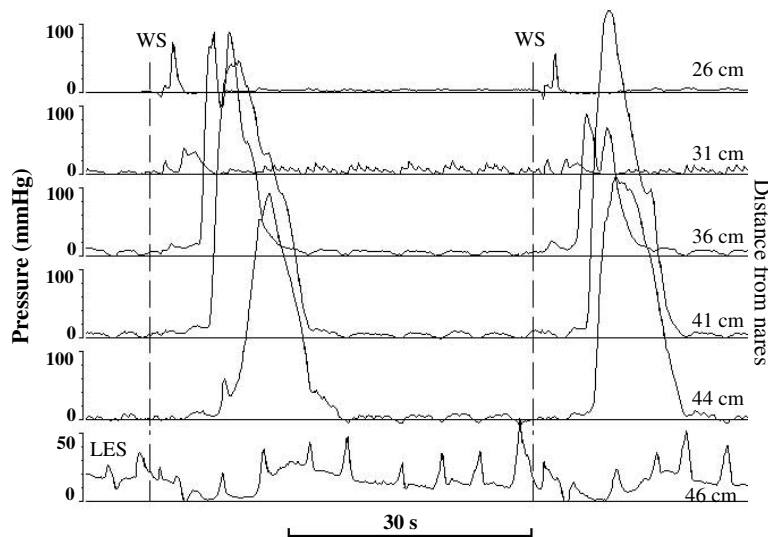
Evaluate oesophageal dysphagia and/or chest pain when causes other than motor disturbance are excluded
Establish the diagnosis of achalasia
Evaluate oesophageal involvement in connective tissue diseases
Determine lower oesophageal sphincter (LES) location for placement of ambulatory pH probe
Evaluate motor function prior to fundoplication
Evaluate dysphagia in the postoperative setting



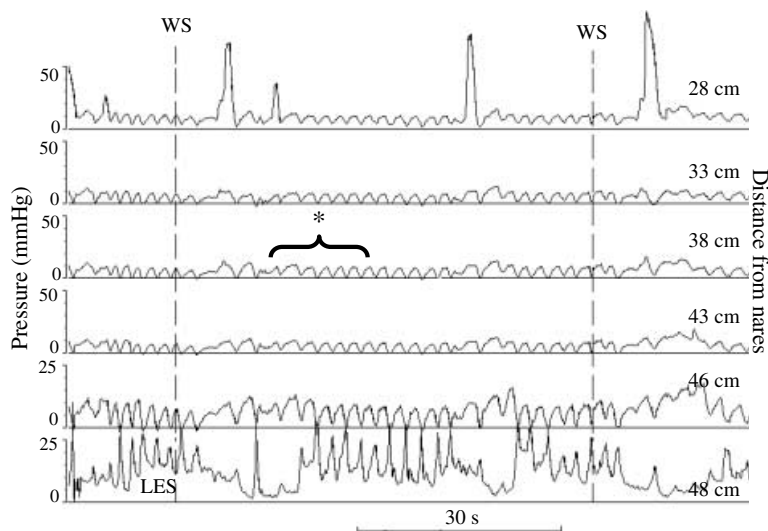
**Figure 3** A manometry from a patient with classic achalasia. Pressure is on the Y-axis and time is on the X-axis. The numbers to the right indicate distance from the nares. WS indicates the occurrence of a wet swallow. The most distal sensor – bottom trace – is in the LES. Note that the LES does not relax with wet swallows. Wet swallows do not produce peristaltic pressure waves in the oesophagus. Instead, there are low amplitude, simultaneous pressure (*isobaric*) waves that are nearly identical in their configuration. This occurs because the oesophagus is behaving as a common cavity so that a change in intraoesophageal pressure anywhere in the oesophagus will be rapidly transmitted to all of the oesophageal lumen. To conceptualize this, think of the oesophagus as a sausage-shaped balloon filled with either air or liquid. The manometry catheter is placed lengthwise within the balloon. If you push or squeeze anywhere over the surface of the balloon without occluding its lumen, an identical increase in pressure will be registered nearly simultaneously at all locations within the balloon.



**Figure 4** A manometry from a patient with diffuse oesophageal spasm. Pressure is on the Y-axis and time is on the X-axis. The numbers to the right indicate distance from the nares. WS indicates the occurrence of a wet swallow. The most distal sensor – bottom trace – is in the LES. The manometric characteristics used to define DES include normal function of the striated muscle oesophagus, wet swallows that produce simultaneous pressure waves of normal or high amplitude  $\geq 30\%$  of the time, and periods of normal peristalsis in the smooth muscle oesophagus. Other abnormalities that may be seen but are not part of the diagnostic criteria include spontaneous pressure waves, repetitive contractions consisting of more than two pressure peaks, high amplitude pressure waves, and prolonged pressure waves.



**Figure 5** A manometry from a patient with nutcracker oesophagus. Pressure is on the Y-axis and time is on the X-axis. The numbers to the right indicate distance from the nares. WS indicates the occurrence of a wet swallow. The most distal sensor – bottom trace – is in the LES. Nutcracker oesophagus is characterized by high amplitude peristaltic pressure waves (mean pressure >180 mmHg) in the smooth muscle oesophagus.



**Figure 6** A manometry from a patient with scleroderma. Pressure is on the Y-axis and time is on the X-axis. The numbers to the right indicate distance from the nares. WS indicates the occurrence of a wet swallow. The most distal sensor – bottom trace – is in the LES. Typical manometric findings of systemic sclerosis (SSc) include low amplitude or absent peristaltic pressure waves in the smooth muscle oesophagus and a low-pressure, normally relaxing lower oesophageal sphincter (LES). In general, the striated muscle portion of the oesophagus (top trace, 28 cm) functions normally. \*In the absence of oesophageal contraction the artefact because of the respiratory cycle can be readily seen.

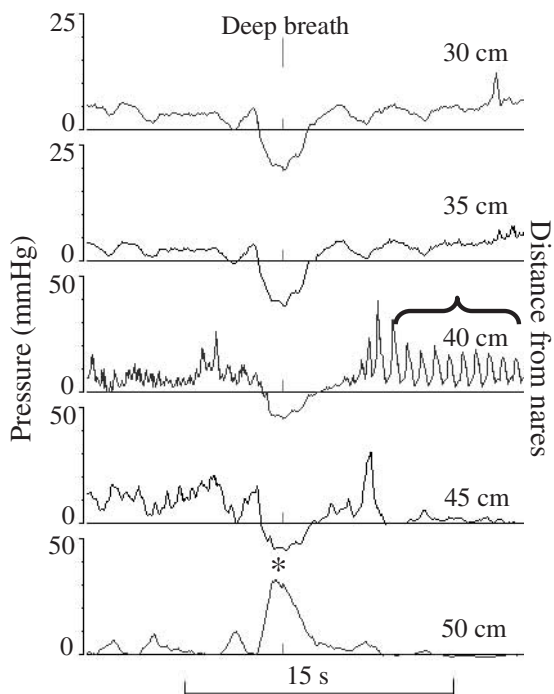
anaesthesia may or may not be used, but its use should be documented. A swallow-recording device is desirable because it provides reliable identification of the timing of swallowing. A respiration monitor may be helpful but is optional; it helps to identify respiratory artefact.

*Equipment preparation.* The recording equipment should be calibrated and the calibration should be documented in the procedure record. The type of manometry catheter/probe and a description of its configuration should be provided as part of the report or record. Important information regarding the recording includes whether it is a perfused catheter or a solid-state probe, the spacing between pressure sensors, and whe-

ther the catheter has a Dent sleeve. The equipment should be checked to assure that functioning of the recording system and its sensors is accurate prior to intubation. Appropriate care and universal precautions should be employed to prevent transmission of infections or noxious substances. Appropriate cleaning and equipment maintenance should be regularly employed per local infection control and manufacturer's instructions.

*Performance of the study.* The manometry catheter may be placed via the nares or by the mouth; placement via the nares is generally more comfortable for the patient. Additionally, there is less risk of damage to

the probe by biting with transnasal placement. The route of intubation should be documented as part of the record. The patient is placed supine after the catheter is passed. If a perfused system is used, the pressure transducers should be positioned at the same level as the mid-thorax of the patient. The patient is allowed to rest following the insertion of the tube so that they may accommodate to the presence of the catheter. Solid-state transducers will warm to body temperature during this time period. The absence of coughing, repetitive or involuntary swallowing, and gagging or excessive salivation usually indicates accommodation to the catheter. The catheter should be placed so at least the distal recording site is located in the stomach. It is preferable to position the three most distal sensors in the stomach. The effects of deep breathing on the pressure recording verify positioning of the sensors. If the recording site is below the dia-



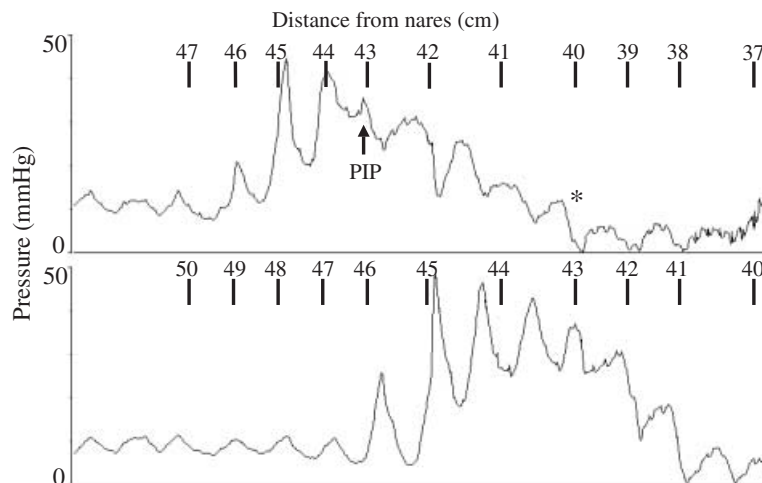
**Figure 7** Localization of the diaphragm by deep inspiration. The location of pressure sensors relative to the diaphragm can be determined by having the subject take a deep inspiration. Sensors situated below the diaphragm record a deep inspiration as a transient rise in pressure because inspiration increases intra-abdominal pressure. An example is seen in the bottom tracing. Sensors situated above the diaphragm record a deep inspiration as a transient decrease in pressure because inspiration decreases intrathoracic pressure. An example is seen in the top four tracings. The asterisk indicates the location of the diaphragm as determined by this technique. The bracketed area illustrates a prominent artefact from cardiac pulsation characterized by its rapid sinusoidal waveform.

phragm the pressure increases with inspiration, whilst if it is above the diaphragm the pressure decreases (Fig. 7). If the location cannot be verified in this way, fluoroscopy or endoscopy should be used to aid in positioning the catheter. This approach may be particularly useful for patients with the sigmoid-shaped oesophagus of advanced achalasia.

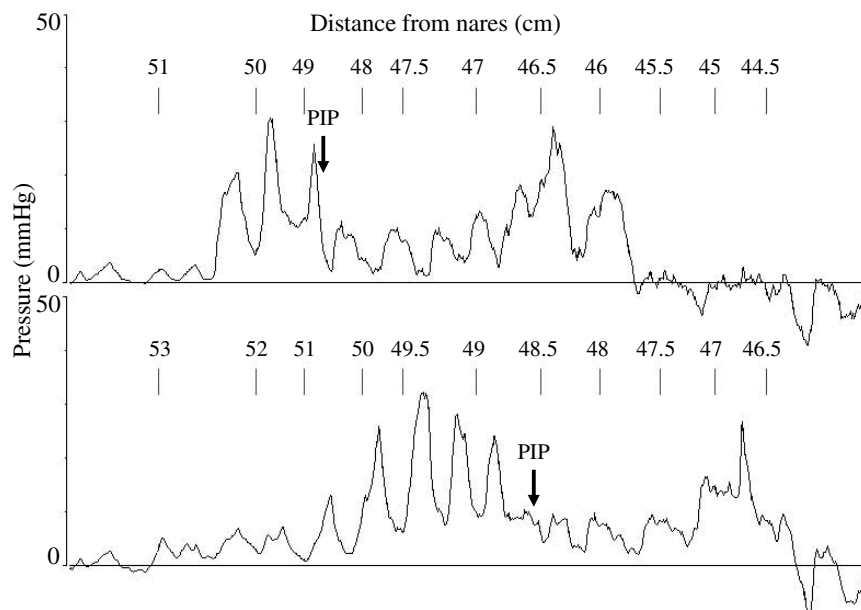
After confirming that the distal sensor(s) is/are in the stomach, the study is started by performing the station pull-through manoeuvre (Fig. 8). This is accomplished by withdrawing the catheter in 1/2–1 cm steps, and observing pressure changes at the recording sites. This part of the study should not be performed with the Dent sleeve but rather by a point sensor located elsewhere on the catheter. The Dent sleeve is not useful for this manoeuvre because it measures pressure simultaneously over a 6-cm segment. The position of pressure sensors relative to the incisors or nares should be documented on the tracing as the station pull-through is being accomplished. The observer looks for a transitory increase in pressure as the sensor is pulled from the low-pressure environment of the gastric lumen, across the zone of high pressure (HPZ) produced by the LES and diaphragm, and into the lower pressure environment of the intrathoracic oesophagus (Fig. 8). Typically, the pressure will be lower on the oesophageal side of the HPZ than on the gastric side. At each step, deep breaths can be used to determine the positions of the recording sites relative to the diaphragm and swallows can be used to identify the LES. The station pull-through manoeuvre gives an indication of the axial location and length of the HPZ. The station pull-through can also discern the pressure inversion point (PIP). The PIP is the location at which the recorded pressure deflection caused by inspiration converts from positive to negative. This pressure inversion occurs as the sensor traverses the level of the diaphragm from the abdominal cavity to the thorax.

The station pull-through can give a clue to the presence of a hiatal hernia (Fig. 9).

**Lower oesophageal sphincter.** The LES is defined as a HPZ at the gastroesophageal junction that relaxes with swallowing. The recording port or the Dent sleeve is placed within the HPZ to record the baseline LES pressure. The LES pressure is measured relative to intragastric pressure. Simultaneous recording of intragastric and LES pressure facilitates this determination, but intragastric pressure can also be ascertained at the time of the station pull-through. It is useful to measure resting LES pressure over several minutes because it varies over time and may be altered reflexively by movement of the catheter.



**Figure 8** Locating the high-pressure zone using the station pull-through technique. The manoeuvre is accomplished by placing the distal pressure sensors in the stomach, withdrawing the catheter in 1/2–1 cm steps, and observing pressure changes at the recording sites at each step. This tracing was made by two sensors spaced 3 cm apart. Pressure is on the Y-axis and time is on the X-axis. The numbers above each tracing indicate distance from the nares. The pressure sensors identify a zone of high pressure as they are pulled from the stomach into the oesophagus. Contraction of the lower oesophageal sphincter (LES) and diaphragm normally contribute to this high-pressure zone. Oscillations in the pressure profile are produced by respiration. When both sensors are in the stomach, respiratory oscillations in pressure are in phase, in the same direction. At some point during the pull-through, at 43 cm from the nares in this example, the pressure oscillation at the more proximal site reverses its direction. This is the pressure inversion point (PIP). It is the location at which pressure produced by inspiration converts from a positive pressure deflection to a negative pressure deflection. The PIP is where the pressure sensor crosses the diaphragm to enter the thoracic cavity. Note that the intragastric pressure is higher than the intraoesophageal pressure. Not seeing this pressure gradient is a clue that there may be obstruction at the sphincteric level, as in achalasia.



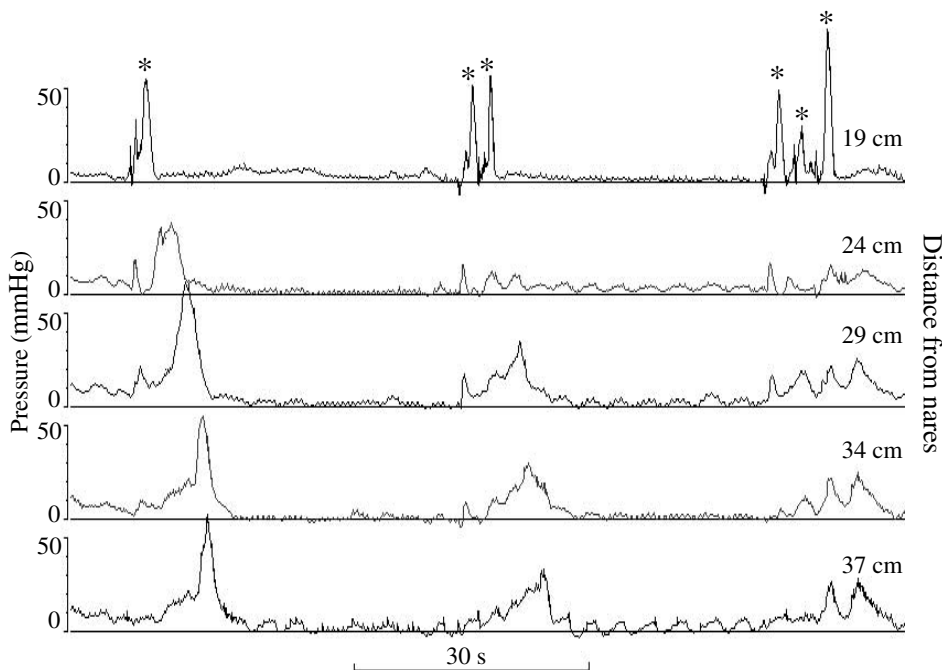
**Figure 9** Hiatal hernia demonstrated by station pull-through. This station pull-through was performed on a patient with a hiatal hernia. Pressure is on the Y-axis and time is on the X-axis. The numbers above each tracing indicate distance from the nares. Notice that the high-pressure zone consists of two pressure peaks. The first peak, to the left, is associated with the pressure inversion point (PIP) suggesting that it is the pressure produced by the diaphragm. The second peak, to the right, is above the diaphragm, and represents the pressure produced by the lower oesophageal sphincter (LES). This pattern is sometimes called the double hump sign.

Valid measures of LES pressure can be made in several ways. Typically, the pressure in the HPZ varies cyclically (like a sine wave) with respiration. Traditionally, most manometrists use the midpoint (average pressure) of the cyclically changing HPZ pressure to calculate LES pressure. This pressure derives from components of the LES and the diaphragm. The peak or trough pressure may also be used. The pressure at the end of unforced expiration represents mostly the LES. The other method that has been used is the peak pressure during a rapid pull through manoeuvre. During this manoeuvre the patient is asked to suspend breathing in relaxed expiration and while the catheter is withdrawn at a constant rate of 1 cm s<sup>-1</sup> either manually or with the assistance of a mechanical puller device.<sup>33</sup> Whatever method is chosen to calculate LES pressure, it should be employed consistently from study to study because normal values will vary depending on the method and catheter used.

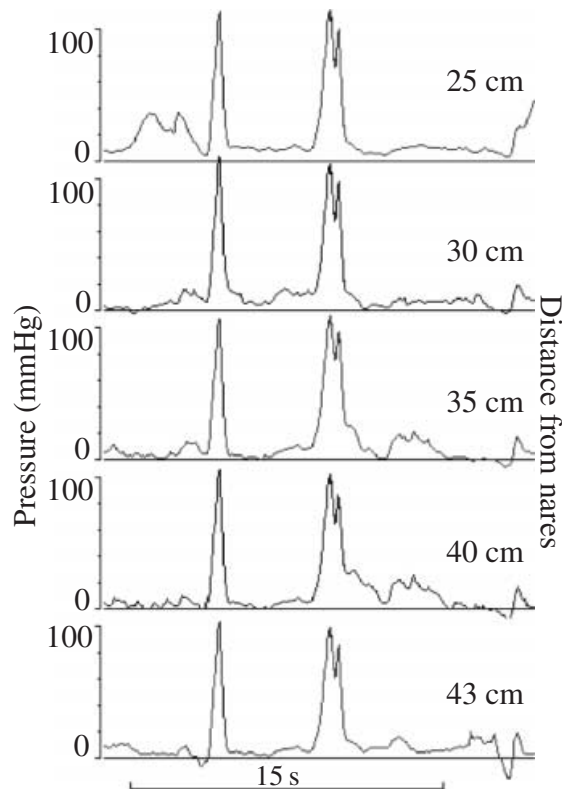
Swallow-induced LES relaxation (Fig. 2) should be evaluated with at least five 'wet swallows', that is 3–5 cc of water at room temperature delivered by syringe. The frequency of swallowing during the study should be often no more than every 20–30 s, to allow return to baseline resting LES pressure, and to

avoid artefact introduced by swallow-induced suppression of oesophageal motor activity. A measurement of the residual pressure, that is the minimum LES pressure (relative to intragastric pressure) during LES relaxation should be recorded. The operator should note whether the LES relaxes to approximate intragastric pressure and recognize pressure overshoot after LES relaxation.

*The oesophageal body.* The motor activity of the oesophagus is evaluated using a manometry catheter configured with at least three point pressure sensors positioned at 3–5 cm intervals along its length. The catheter is positioned so that the most distal of these sensors is just above the LES or if there are sufficient sensors with one sensor in the LES. After positioning the catheter, the function of the smooth muscle oesophagus is evaluated by having the patient take 10 water swallows (Fig. 2). Again, at least 20–30 s should elapse between the swallows. Rapidly repeated swallowing inhibits peristalsis in the smooth muscle oesophagus (Fig. 10).<sup>60</sup> If the pressure sensors of the catheter span 10 cm or less it is necessary to place the catheter more proximally to study the upper half of the oesophageal body. Wet swallows normally produce a propagated



**Figure 10** Effect of multiple swallows on oesophageal motor function. Pressure is on the Y-axis and time is on the X-axis. The numbers to the right indicate distance from the nares. The sensors are positioned such that the most proximal – top trace – is in the pharynx, and the others are located in the oesophagus. Asterisks indicate swallows. Notice that repetitive swallowing disrupts the normal peristaltic sequence.



**Figure 11** Pressure transients produced by coughing. Pressure is on the Y-axis and time is on the X-axis. The numbers to the right indicate distance from the nares. The sharp pressure transients seen here are the result of coughing. Notice that they are short lived, simultaneous and nearly identical in appearance. Similar pressure transients are seen with gagging.

(peristaltic) pressure wave along the length of the oesophagus (Fig. 2). If no peristalsis is apparent, the sensors are checked by having the patient cough. This manoeuvre produces a nearly identical, rapid, pressure transient simultaneously at all of the recording sites (Fig. 11). Malfunction is indicated if the rapid pressure transient is not seen or it has a very slow rise time. These artefacts may be seen in perfused manometry systems when there is a problem with the catheter perfusion system. Problems may include air in the perfusion system, loss of pressurization of the system, obstruction to flow in the system, a fluid reservoir that is empty or bad connections between pressure transducers and the recording equipment. Failure of solid-state pressure sensors or the recording system also may occur.

To complete the study, the catheter is pulled back until the UES is identified as a zone of high resting pressure that decreases promptly with wet swallows (Fig. 1). The distance of the UES from the incisors or nares should be documented. Detailed examination of UES and pharyngeal function is not considered part of

the standard manometry and may require special equipment and expertise.

### Analysis of the recording

Analysis of the oesophageal manometry is focused primarily on describing the motor functions of the LES and oesophageal body and distinguishing artefacts from these motor functions. To do this effectively and accurately the clinician reading the study should have a firm grasp of the principles of oesophageal motor physiology, an understanding of the recording techniques used, and familiarity with oesophageal motor disturbances. The clinician interpreting the test must also be made aware of any special circumstances such as movement, gagging or repetitive swallowing by the patient during the study. Despite attempts at making the reading of oesophageal manometry objective, some of its interpretation remains subjective, and no analytical approach is universally accepted.

Analysis of LES motor function includes assessing its location, resting pressure and the characteristics of its relaxation. The axial location of the LES is best determined during the station pull-through manoeuvre. The proximal extent of the LES is defined as the location, during the pull-through manoeuvre, at which the pressure first drops to intraoesophageal pressure (Fig. 8).

*Reporting the results.* The report should contain general information: the patient identifier, date and time of the procedure, whether the catheter was placed via the mouth or the nares, the type and the configuration of catheter, the type of recording device, and any medications given during the procedure. The data to be reported are summarized in Table 2.

A description of the LES should include the distance from the nares or incisors to the top of the HPZ. Reporting the length of the sphincter is optional but requested by some physicians. The report should include the baseline LES pressure and residual pressure during maximal swallow-induced relaxation. The residual pressure is the pressure at the nadir of the relaxation relative to intragastric pressure (Table 3).

The oesophageal body report should include a description of the configuration of the pressure waves within the oesophagus and their peristaltic nature. To be classified as a pressure wave produced by a contraction, the pressure increase should be at least 20 mmHg. Characteristics of the wave configuration are used to determine if the motility pattern deviates from normal toward hyper- or hypomotility. These include the amplitude and duration of pressure waves, and whether

**Table 2** Components of the manometry report

- 
- (A) General information
- (1) Patient identifier
  - (2) Date and time of procedure
  - (3) Indication for the procedure
  - (4) Placement of catheter via the mouth or nares
  - (5) Type and configuration of the catheter
  - (6) Type of recording device
  - (7) Medications used during the procedure
- (B) Lower oesophageal sphincter
- (1) Location of the upper border of the high-pressure zone from the nares or incisors
  - (2) Length of the high-pressure zone (optional)
  - (3) Baseline lower oesophageal sphincter (LES) pressure (normal values will vary for laboratory and method)
    - (a) Indicate whether pressure is measured at end-inspiration, end-expiration or at mid-respiratory cycle
  - (4) Residual pressure during maximal LES relaxation
  - (5) Nature of the oesophago-gastric pressure gradient, i.e. normal or reversed (optional)
- (C) Oesophageal body
- (1) Oesophageal pressure waves are defined as transient increases in intraoesophageal pressure of >20 mmHg above baseline
  - (2) Percentage of *wet* swallows that produce
    - (a) Normally propagated peristaltic pressure waves
    - (b) Failed peristalsis
    - (c) Simultaneous pressure waves
    - (d) Feeble peristaltic pressure waves (<30 mmHg) (optional)
    - (e) Oesophageal pressure waves that are repetitive (>3 pressure peaks at a recording site; recording the percentage of double-peaked waves is optional)
  - (3) Velocity of peristalsis (optional)
  - (4) Record mean wave amplitude and duration in the distal oesophagus
- (D) Upper oesophageal sphincter
- (1) Subjective evaluation of relaxation with swallowing
  - (2) Location from the nares or incisors
- (E) Interpretation of results
- (1) A meaningful interpretative summary of the manometric findings should be provided
  - (2) A computerized review does not supplant the need for manual review
- 

**Table 3** Outline of components of oesophageal manometry

- 
- (A) Patient preparation
- (1) Nothing per os (NPO) >4–6 h
  - (2) Ideally, the patient should be off all medications that may affect oesophageal motor function for 24 h ( $\beta$ -adrenergic antagonists, nitrates, calcium-channel antagonists, anticholinergic agents, prokinetic agents, nicotine, narcotics and caffeine)
  - (3) Make a record of medications that the patient is using
  - (4) Sedation should be used as part of the patient preparation for oesophageal manometry only if it is absolutely needed to complete the study. The use of sedation should be documented
  - (5) Local anaesthesia may or may not be used. Its use should be documented
  - (6) Accurate detection of swallowing is desirable, and can be achieved by concurrent, online, intraluminal recording of swallowing
  - (7) A respiratory monitor is helpful but optional. It allows reliable identification of respiratory artefact
- (B) Equipment preparation
- (1) Calibrate the equipment and document it on recording
  - (2) Record the catheter type and configuration
  - (3) Check to assure functioning of the recording device prior to intubation
    - (a) Are the recording devices turned on?
    - (b) Are all of the appropriate connections made and documented?
- (C) Performing the study
- (1) The manometry catheter may be placed via the nares or mouth – document method. *Trans*-nasal placement of the manometry probe should be used if *trans*-nasal placement of a pH probe will be carried out subsequently
-

Table 3 *Continued*

- 
- (2) The patient should be in the recumbent position after the catheter is passed
  - (3) Wait 5–10 min to allow the patient to accommodate to the catheter and the solid-state sensors to reach body temperature
  - (4) If a perfused catheter system is being used, the patient should be placed so that all of the pressure transducers are at the same level as the mid-axillary line of the recumbent patient
  - (5) At least the most distal (preferably three of the most distal) recording site(s) should be in the stomach and their intragastric (subdiaphragmatic) location verified. If a Dent sleeve catheter is being used, the sleeve and the recording port just above it should be positioned in the stomach
  - (6) Identification of the high-pressure zone. This part of the study is performed as the catheter is withdrawn in a stepwise fashion, the *station pull-through technique* (Fig. 7).
    - (a) The station pull-through is performed by pulling the catheter back in 0.5–1.0 cm steps
    - (b) The distances of the recording sites from the incisors or nares should be documented on the recording as the station pull-through is being accomplished
    - (c) At each step swallows and deep inspirations can be used to identify the lower oesophageal sphincter (LES)
    - (d) The high-pressure zone (HPZ) (Fig. 7)
      - (i) Record the distance of the HPZ from the incisors or nares
      - (ii) The length of the high-pressure zone can be measured
    - (e) The *pressure inversion point* (PIP) – the location at which pressure converts from positive to negative deflection on inspiration
  - (7) The LES – a zone of high pressure at the gastroesophageal junction that normally relaxes with swallowing
    - (a) Measure LES resting pressure; position the recording port(s) or Dent sleeve within the HPZ and record the mean baseline LES pressure
      - (i) LES pressure = pressure of HPZ – gastric pressure
      - (ii) It is best if pressures in the HPZ and stomach are recorded simultaneously at least in two sensors or two passes with one sensor
    - (b) Examine LES relaxation
      - (i) Use at least five wet swallows of  $\geq 3$  cc (preferably 5 cc) of water at room temperature
      - (ii) At least 20 s should elapse between swallows
      - (iii) Measure the residual LES pressure relative to intragastric pressure – the minimum LES pressure during LES relaxation produced by swallowing
      - (iv) Recognize pressure overshoot after LES relaxation
  - (8) The oesophageal body
    - (a)  $\geq 3$  pressure sensors positioned 3–5 cm apart should be located above the LES
    - (b) Both the distal (lower) and proximal (upper) oesophageal body regions should be examined
    - (c) At least 10 wet swallows should be performed in the lower and upper oesophagus
    - (d) Swallows should occur at intervals 20–30 s
    - (e) If no peristalsis is seen, have the patient cough to check the sensors
  - (9) The upper oesophageal sphincter – measurement of the motor activity of the UES is not part of the minimal study but may be useful when disorders of the striated muscle segment are possible.
    - (a) Identify a region of increased resting pressure in the upper oesophagus that relaxes with swallowing
    - (b) Verify relaxation subjectively
    - (c) Document the position from the nares or incisors
- 

they have multiple peaks: most authorities place greatest emphasis on the amplitude. Mean values for amplitude and duration are extracted from waves measured from the distal oesophagus as are the percentage of swallows followed by multi-peaked waves. The locations used for these measurements should correspond to the locations used in reports of published normal values. Waves at adjacent recording sites should not have the same morphology, i.e. the pressure waves should not be identical in contour and amplitude. These *isobaric* pressure waves are indicative of a rapidly propagated pressure wave in a common cavity and are seen in achalasia or in a dilated oesophagus (Fig. 3). Peristaltic performance is evaluated by recording the percentage of wet swallows that

produce a normal peristaltic response. Additionally, the percentage of swallows followed by non-peristaltic contraction of simultaneous onset should be noted, as should the number of failed responses. Recording the percentage of swallows accompanied by hypertensive or feeble responses (pressure waves less than 30–35 mmHg in amplitude) is optional, as the mean values for contraction configuration are more commonly used as the determinants of a hyper- or hypomotility disorder. The mean velocity of peristalsis is an optional measurement as a mean value is of less use than the categorization of individual swallows as peristaltic, simultaneous (non-peristaltic), or failed. Motor disorders typically are characterized by peristaltic performance in the distal oesophagus, but comment

on peristaltic features in the proximal oesophagus can be included in the report. Examination of the UES is not considered part of the routine minimal standard oesophageal motility study. Normal values for resting UES pressure and peristaltic pressure waves in the pharynx are not well established. In addition, examination of this region is complicated by technical problems related to anatomy and function of the UES and pharynx. However, it may be used as an adjunctive test for patients in whom there is a high likelihood of disorders affecting the striated muscle. Routine examination of the UES consists of demonstrating its relaxation upon swallowing and documenting its location relative to the nares or incisors. Some investigators use manometric location of the UES to aid in the placement of pharyngeal pH sensors.

## REFERENCES

- Castell DO, Dieterich L, Castell JA. *Esophageal Motility Testing*, 3rd edn. Denver Colorado: Sandhill scientific, 2002.
- Malagelada J-R, Camillieri M, Stanghellini V. *Manometric Diagnosis of Gastrointestinal Motility Disorders*. New York: Thieme, 1986.
- Anuras S. (ed.) *Motility Disorders of the Gastrointestinal tract: Principles and Practice*. New York: Raven Press, 1992.
- Crane RK. (ed.) *Gastrointestinal Physiology II*. Baltimore: University Park Press, 1977.
- Miller AJ. *The Neuroscientific Principles of Swallowing and Dysphagia*. San Diego: Singular Pub. Group, 1999.
- Code CF [and others] *An Atlas of Esophageal Motility in Health and Disease*. Springfield, IL: Thomas, 1958.
- Fransen G, Valembos P. Basic data anatomy and embryology. In: Vantrappen G, Helleman J, eds. *Diseases of the Esophagus*. New York: Springer-Verlag, 1978: 1–15.
- Kahrilas PJ, Dodds WJ, Dent J, Logemann JA, Shaker R. Upper esophageal sphincter function during deglutition. *Gastroenterology* 1988; **95**: 52–62.
- Car A, Roman C. Deglutitions et contractions oesophagiennes reflexes produites par la stimulation du bulbe rachidien. *Exp Brain Res* 1970; **11**: 75–92.
- Winans CS. The pharyngoesophageal closure mechanism: a manometric study. *Gastroenterology* 1972; **63**: 768–77.
- Welch RW, Luckmann K, Ricks PM, Drake ST. Manometry of the normal upper esophageal sphincter and its alterations in laryngectomy. *J Clin Invest* 1979; **63**: 1036–41.
- Kahrilas PJ, Dodds WJ, Dent J, Haeberle B, Hogan WJ, Arndorfer RC. The effect of sleep, spontaneous gastroesophageal reflux and a meal on UES pressure in humans. *Gastroenterology* 1987; **92**: 466–71.
- Kahrilas PJ, Dent J, Dodds WJ, Hogan WJ, Arndorfer RC. A method for continuous monitoring of upper esophageal sphincter pressure. *Dig Dis Sci* 1987; **32**: 121–8.
- Jacob P, Kahrilas PJ, Herzon G, McLaughlin B. Determinants of upper esophageal sphincter pressure in dogs. *Am J Physiol* 1990; **259**: G245–51.
- Kahrilas PJ, Clouse RE, Hogan WJ. Esophageal manometry, American gastroenterology association policy and position statement. *Gastroenterology* 1994; **107**: 1865–894.
- Shipp T, Deatsch WW, Robertson K. Pharyngoesophageal muscle activity during swallowing in man. *Laryngoscope* 1970; **80**: 1–6.
- Cook IJ, Dodds WJ, Dantas RO *et al*. Opening mechanisms of the human upper esophageal sphincter. *Am J Physiol* 1989; **257**: G748–59.
- Castell JA, Dalton CB, Castell DO. Effects of body position and bolus consistency on the manometric parameters and coordination of the upper esophageal sphincter and pharynx. *Dysphagia* 1990; **5**: 179–86.
- Bombeck CT, Dillard DH, Nylus LM. Muscular anatomy of the gastroesophageal junction and role of the phrenoesophageal ligament: autopsy study of sphincter mechanism. *Ann Surg* 1966; **164**: 643–54.
- Christensen J, Robison BA. Anatomy of the myenteric plexus of the opossum esophagus. *Gastroenterology* 1982; **83**: 1033–42.
- Roman C. Nervous control of esophageal peristalsis. *Journal de Physiologie* 1966; **58**: 79–108.
- Higgs B, Kerr FWL, Ellis FH. The experimental production of esophageal achalasia by electrolytic lesions in the medulla. *J Thorac Cardiovasc Surg* 1965; **50**: 613–25.
- MacGilchrist AJ, Christensen J, Rick GA. The distribution of myelinated fibers in the myenteric plexus of the opossum esophagus. *J Auton Nerv Syst* 1991; **35**: 227–36.
- Conklin JL, Christensen J. Motor functions of the esophagus. In: Johnson LR, Christensen J, Alpers D, Jacobsen ED, Walsh J, eds. *Physiology of the Gastrointestinal Tract*, 3rd edn. Chapter 4. 1994: 33–40.
- Doty RW. Neural organization of deglutition. In: Code CF, ed. *Handbook of Physiology*, Section 6. Alimentary Canal Vol 4, 1968: 1861–902.
- Massey BT, Dodds WJ, Hogan WJ, Brasseur JG, Helm JF. Abnormal esophageal motility. An analysis of concurrent radiographic and manometric findings. *Gastroenterology* 1991; **101**: 344–54.
- Clouse RE, Hallett JL. Velocity of peristaltic propagation in distal esophageal segments. *Digestive Dis Sci* 1995; **40**: 1311–6.
- Humphries TJ, Castell DO. Pressure profile of esophageal peristalsis in normal humans as measured by direct intraesophageal transducers. *Am J Digestive Dis* 1977; **222**: 641–5.
- Kahrilas PJ, Dodds WJ, Hogan WJ. The effect of peristaltic dysfunction on esophageal volume clearance. *Gastroenterology* 1988; **94**: 73–80.
- Dodds WJ, Stewart ET, Hodges D, Zboralske FF. Movement of the feline esophagus associated with respiration and peristalsis. *J Clin Invest* 1973; **52**: 1–13.
- Edmundowicz SA, Clouse RE. Shortening of the esophagus in response to swallowing. *Am J Physiol* 1991; **260**: G512–6.
- Lieberman-Meffert D, Allgower M, Schmid P, Blum AL. Muscular equivalent of the lower esophageal sphincter. *Gastroenterology* 1979; **76**: 31–8.
- Goyal RK, Rattan S. Genesis of basal sphincter pressure: effect of tetrodotoxin on lower esophageal sphincter pressure in opossum in vivo. *Gastroenterology* 1976; **71**: 62–7.
- Holloway RH, Blank EL, Takahashi I, Dodds WJ, Dent J, Sarna SK. Electrical control activity of the lower esophagus.

- geal sphincter in unanesthetized opossums. *Am J Physiol* 1987; **252**: G511–21.
- 35 Dodds WJ, Hogan WJ, Stef JJ, Miller WN, Lydon SB, Arndorfer RC. A rapid pull-through technique for measuring lower esophageal sphincter pressure. *Gastroenterology* 1975; **68**: 437–43.
- 36 Dodds WJ, Hogan WJ, Reid DP, Stewart ET, Arndorfer RC. A comparison between primary esophageal peristalsis following wet and dry swallows. *J Appl Physiol* 1973; **35**: 851–7.
- 37 Rossiter CD, Norman WP, Jain M, Hornby PJ, Benjamin S, Gillis RA. Control of the lower esophageal sphincter pressure by two sites in the dorsal motor nucleus of the vagus. *Am J Physiol* 1990; **256**: G899–906.
- 38 Paterson WC, Anderson MA, Anand N. Pharmacological characterization of lower esophageal sphincter relaxation induced by swallowing, vagal efferent nerve stimulation, and esophageal distension. *Can J Physiol Pharmacol* 1992; **70**: 1011–5.
- 39 Murray J, Du C, Ledlow A, Bates JN, Conklin JL. Nitric oxide: mediator of nonadrenergic noncholinergic responses of opossum esophageal muscle. *Am J Physiol* 1991; **261**(*Gastrointest. Liver Physiol.* 24): G401–6.
- 40 Tøttrup A, Svane D, Forman A. Nitric oxide mediating NANC inhibition in opossum lower esophageal sphincter. *Am J Physiol* 1991; **260**: G385–9.
- 41 Mittal RK, Rochester DF, McCallum RW. Sphincteric action of the diaphragm during a relaxed lower esophageal sphincter in humans. *Am J Physiol* 1989; **256**: G139–44.
- 42 Boyle JT, Altschuler SM, Nixon TE, Tuchman DN, Pack AI, Cohen S. Role of the diaphragm in the genesis of lower esophageal sphincter pressure in the cat. *Gastroenterology* 1985; **88**: 723–30.
- 43 Altschuler SM, Boyle JT, Nixon TE, Pack AI, Cohen S. Simultaneous reflex inhibition of lower esophageal sphincter and crural diaphragm in cats. *Am J Physiol* 1985; **249**: G586–91.
- 44 Diamant NE. Physiology of the esophagus. In: Sleisenger MH, Fordtran JS, eds. *Gastrointestinal Disease: Pathophysiology, Diagnosis, Management*, 4th edn. Philadelphia: Saunders, 1989: 548–59.
- 45 Dent J, Dodds WJ, Friedman RH *et al.* Mechanism of gastroesophageal reflux in recumbent asymptomatic human subjects. *J Clin Invest* 1980; **65**: 256–67.
- 46 Wilson JA, Pryde A, Macintyre CCA, Heading RC. Normal pharyngo-esophageal motility, a study of 50 healthy subjects. *Dig Dis Sci* 1989; **34**: 1590–9.
- 47 Richter JE, Wu WC, Johns DN *et al.* Esophageal manometry in 95 healthy adult volunteers. *Dig Dis Sci* 1987; **32**: 583–92.
- 48 Kahrilas PJ, Dodds WJ, Hogan WJ, Kern M, Arndorfer RC, Reece A. Peristaltic dysfunction in peptic esophagitis. *Gastroenterology* 1986; **91**: 897–904.
- 49 Biancani P, Goyal RK, Phillips A, Spiro HM. Mechanics of sphincter action. Studies on the lower esophageal sphincter. *J Clin Invest* 1973; **52**: 2973–8.
- 50 Lydon SB, Dodds WJ, Hogan WJ, Arndorfer RC. Effect of manometric assembly diameter on intraluminal esophageal pressure recording. *Am J Dig Dis* 1975; **20**: 968–70.
- 51 Dodds WJ, Stef JJ, Hogan WJ. Factors determining pressure measurement accuracy by intraluminal esophageal manometry. *Gastroenterology* 1976; **70**: 117–23.
- 52 Arndorfer RC, Stef JJ, Dodds WJ, Linehan JH, Hogan WJ. Improved infusion system for intraluminal esophageal manometry. *Gastroenterology* 1977; **73**: 23–27.
- 53 Dent JA. A new technique for continuous sphincter pressure measurement. *Gastroenterology* 1976; **71**: 763–7.
- 54 Orłowski J, Dodds WJ, Linehan JH, Dent J, Hogan WJ, Arndorfer RC. Requirements for accurate manometric recording of pharyngeal and esophageal peristaltic pressure waves. *Invest Radiol* 1982; **17**: 567–72.
- 55 Weihrauch TR. *Esophageal Manometry, Methods and Clinical Practice*. Baltimore: Urban & Schwarzenberg, 1981.
- 56 Marples MJ, Mughal M, Banciewicz J. Can an esophageal pH electrode be accurately positioned without manometry? In: Siewert JR, Holscher AH, eds. *Diseases of the Esophagus*. New York: Springer-Verlag, 1987: 789–91.
- 57 Mattox HE, Richter JE, Sinclair JW, Price JE, Case LD. The gastroesophageal pH step up inaccurately locates the proximal lower esophageal sphincter. *Dig Dis Sci* 1992; **37**: 1185–91.
- 58 Joelsson BE, DeMeester TR, Skinner DB, Lafontaine E, Waters PF, O'Sullivan GC. The role of the esophageal body in the antireflux mechanism. *Surgery* 1982; **92**: 417–24.
- 59 Mughal MM, Banciewicz J, Marples M. Oesophageal manometry and pH recording does not predict the bad results of Nissen fundoplication. *Br J Surg* 1990; **77**: 43–45.
- 60 Sifrim D, Janssens J, Vantrappen G. A wave of inhibition precedes primary peristaltic contractions in the human esophagus. *Gastroenterology* 1992; **103**: 876–82.

## APPENDIX 1

Additional Members of the AMS and ENMS working group on oesophageal manometry. Georg Stacher, Fabio Baldi, Daniel Sifrim, Alin Batoman, Richard Gilbert, Jo Barlow, Additional input was received from Joel Richter, Donald Castell, Bry Wyman, Henry Parkman, Sidney Phillips and James Christensen in the development of this document.